

9/11/24 Morning Report with @CPSolvers

“One life, so many dreams” Case Presenter: Minahil Ramzan (@minahilramzan09) Case Discussants: Sharmin (@Sharminzi) and Parisa (@parisaabediii)

CC: A 54 Y/O M who presented to the clinic with weakness and dizziness for 4 days.

HPI: the patient presented with these persistent sx that began 4 days ago. One week ago the patient experienced an episode of moderate chest pain, described as pressure like sensation radiating to his left arm. The chest pain was severe in intensity and lasted for approximately 20-30 min before spontaneously resolving. The patient did not seek any medical attention as the pain subsided on its on. Since the episode of chest pain he has not experienced any further discomfort but continues to feel weak and dizzy. The persistent dizziness and weakness prompted him to visit the clinic.

PMH: not significant

Fam Hx:
Not significant

Meds:

Soc Hx:
Non smoker , did not use illicit drug or alcohol.
No recent travel hx

Health-Related Behaviors:

Allergies: NKA

Vitals: T: afebrile HR:90 BP:77/57 RR:20 96% RA

Exam:

Gen: lying comfortably on bed
HEENT: no lymphadenopathy, no jvp
CV: normal S1/S2, no murmurs
Pulm: CTAB
Abd: soft non tender, BS Positive
Neuro: AOX3, no cranial or motor defects
Extremities/skin: no rashes or lesions

Notable Labs & Imaging:

Hematology:

WBC: 6.86 Hgb:14.6 hct 41.8 Plt: 274

Chemistry:

Na: K: Cl: HCO3: BUN: 25 Cr:0.9
AST: 25 ALT: 30 Alk-P: 73 Bili:0.51 rest nl

Troponin high 0.100

LDH 264

Lipid profile: S.triglyceride 160 S. cholesterol 124 S.HDL 34 S.LDL 74

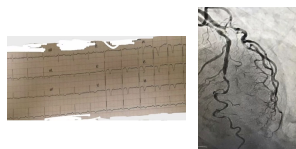
Imaging:

EKG:HR is 75 beats/min , rhythm is normal , normal morphological p wave indicating sinus rhythm , narrow QRS complexes and T wave inversion in lead V1-V4

Echocardiogram: normal, EF 60%

High suspicion for CAD, Coronary angiography was done which showed severe stenosis on the LAD . the patient subsequently underwent successful PCI with the stent placement.

Dx: Wellen Syndrome



Problem Representation: A 54 Y/O M presents complaining of weakness and dizziness of 4 days duration with a recent hx of chest pain. Labs showed elevated troponin and ECG showing t wave inversions in leads v1-v4.

Teaching Points (@maryanamribeiro):

- *Weakness and fatigue:* non-specific symptoms - wide ddx
- *Weakness* - associated with focality? If so, neurological investigation should be prioritized
- *Chest pain:* STEMI x MSK pain
- Episodes are related to each other? ACS prior, got resolved and now presenting complications of that? - *Cardiopulmonary system MUST be investigated*
- Low blood pressure -> resuscitation. Management > diagnosis. Because we may be dealing with a heart condition in this case -> caution is needed when giving fluids!**
- Hypotensive shock: obstruction x cardiogenic x distributive
- Arrhythmias (post-STEMI complication), valve ruptures, tamponade, cardiogenic shock?, no evidence of heart failure (no JVD, no crackles)
- High troponin & ECG with signs of ischemia -> ACS? CAD? -> Close monitoring
- **Wellen syndrome:** V2 and V3 showing deeply inverted T waves secondary to **proximal LAD stenosis**
- Multivessel disease: CABG > stent
- Identify reversible causes: diabetes, HTN