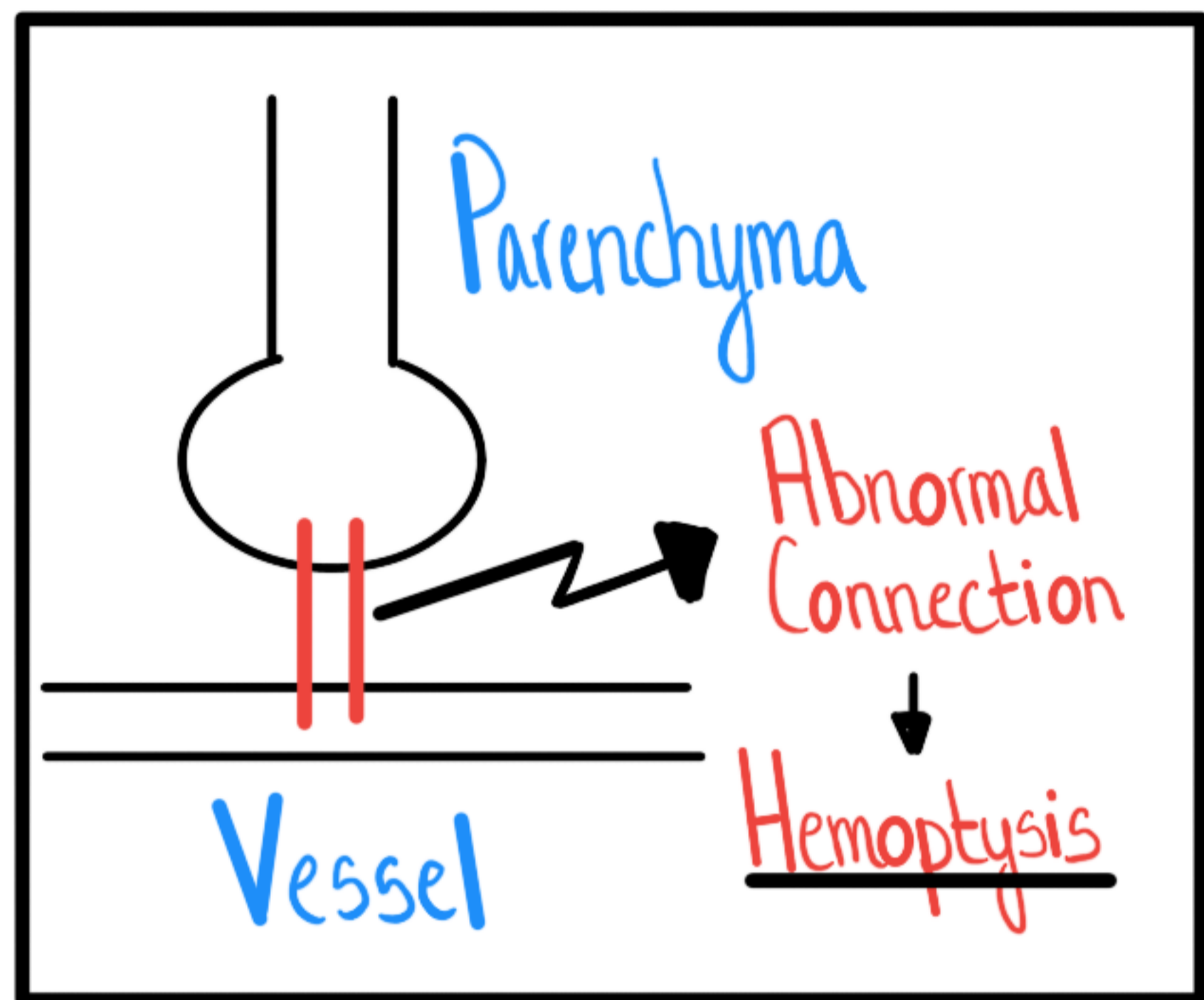


# Hemoptysis



## Parenchyma

- Bronchitis 70%
- Bronchiectasis
- Endobronchial Lesion
- Cavitory Lesion

## Vascular

### Artery

- Pulmonary { Embolism  
Aneurysm

• Tracheoinnominate  
Fistula

• Aortobronchial  
Fistula

• Dieulafoy

### Capillary

• DAH

• AVM

### Vein

• CHF  
Mitral Valve  
Dz

• PVOI