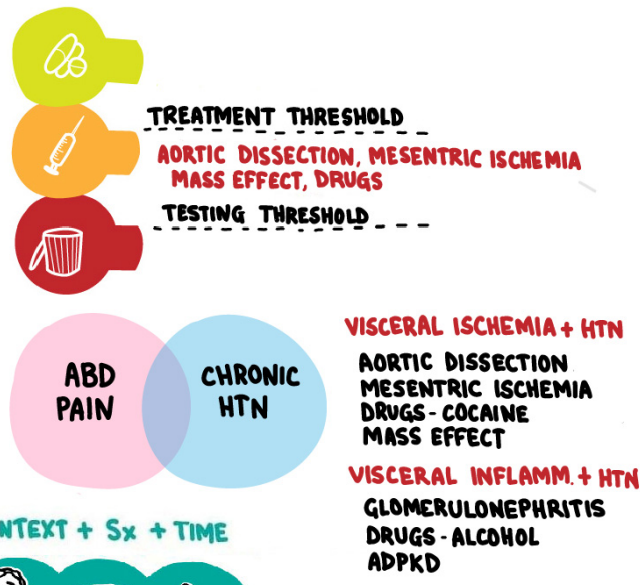
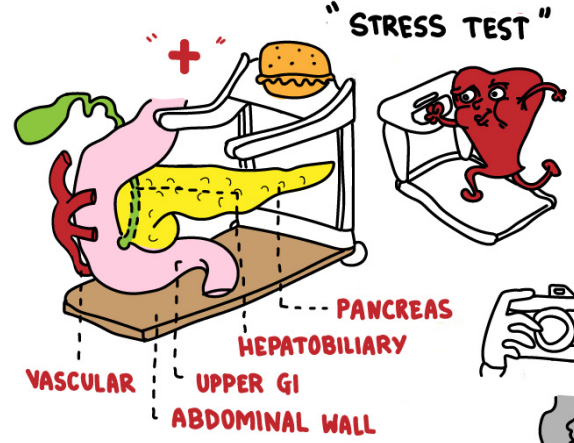
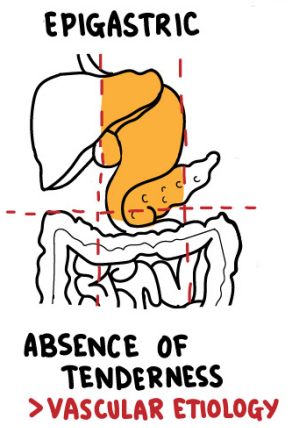
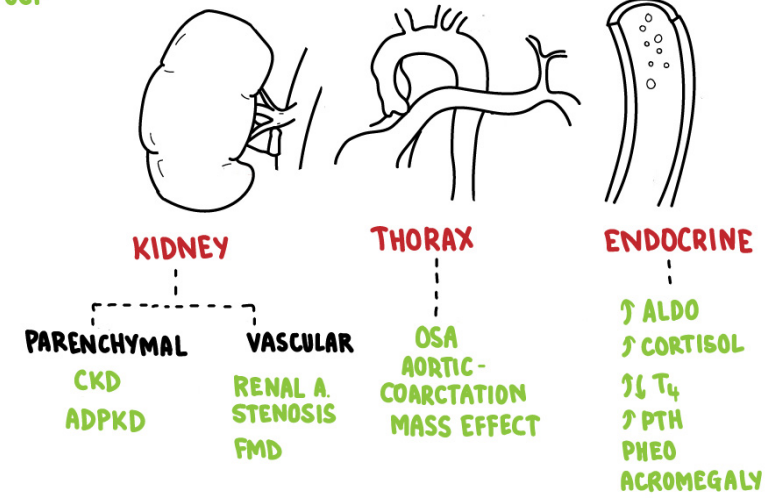
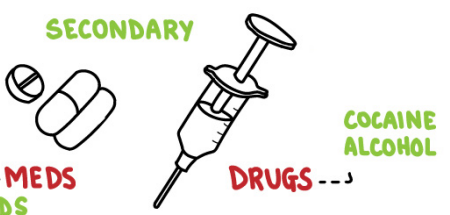
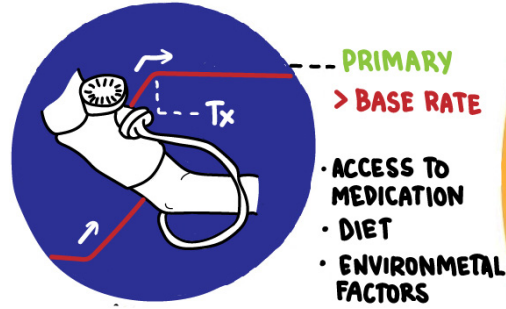
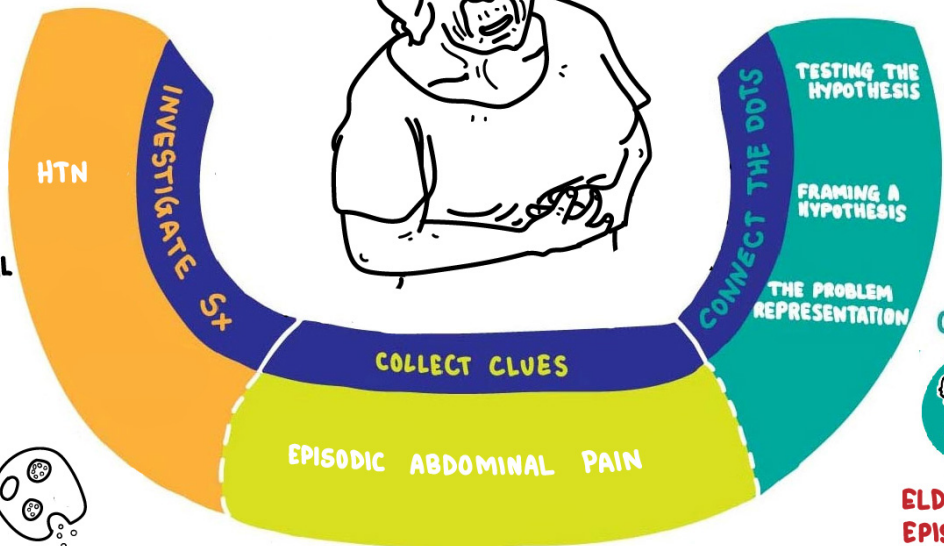

PANCREATIC ADENOCA.



ELDERLY FEMALE + HTN ON Tx + ELEVATED BP + EPISODIC POST PRANDIAL EPIGASTRIC PAIN + WEIGHT LOSS

