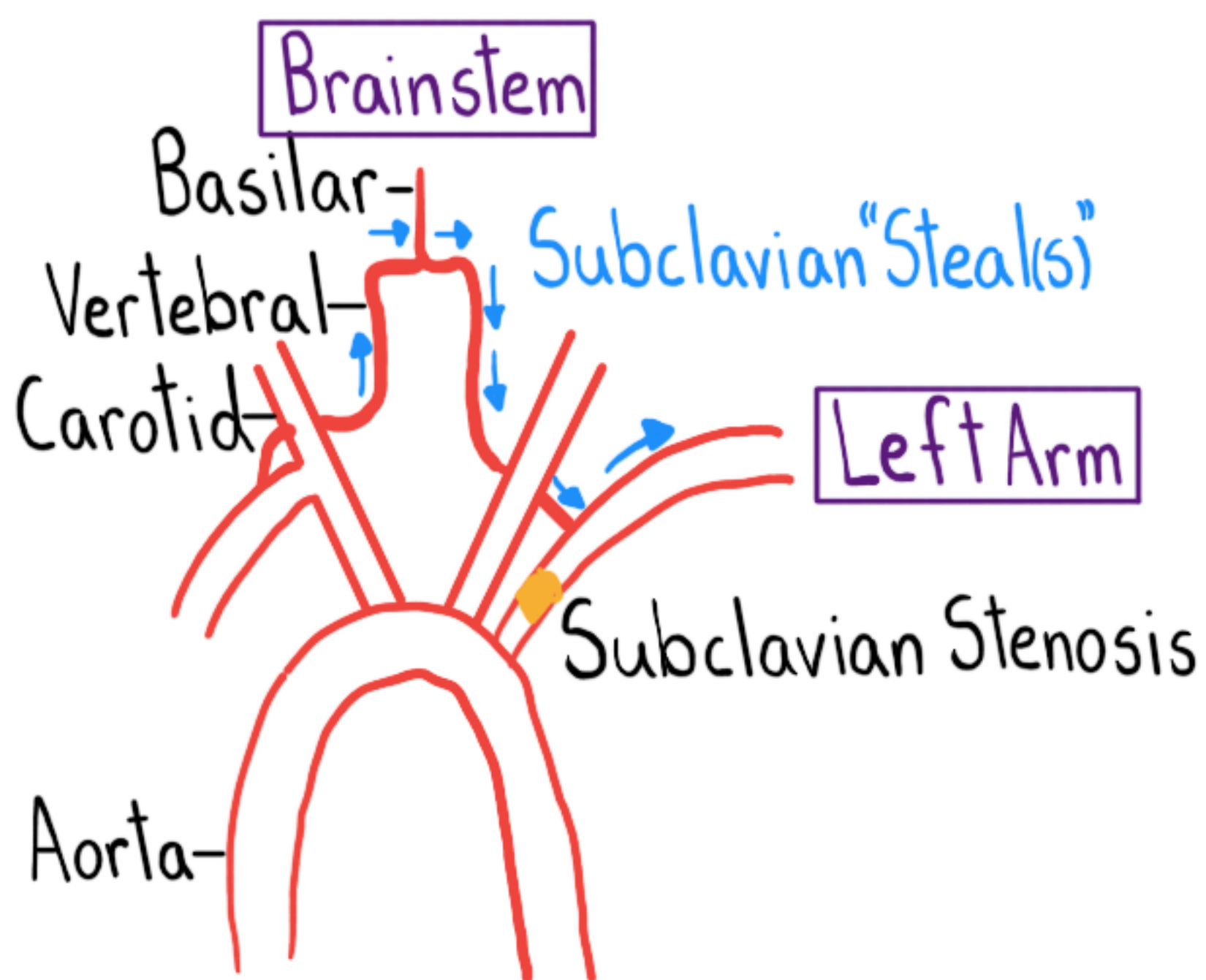


# Subclavian Steal Syndrome



## How?

- Proximal (to Vertebral) Subclavian Artery Lesion
- ↓ Pressure In Arm Distal to Lesion
- Subclavian Steal "s" From Vertebrobasilar System



## Who?

- PAD
- M > W

## Who Else?

- Large Vessel Vasculitis
- Thoracic Outlet Syndrome
- Surgical Repair, Coarctation Aorta

## What?

Ischemic Symptoms in Minority w/ "Steal"

### Arm

- Exercise → Pain, Fatigue, Coolness, Neuropathy

### Brainstem

#### Precipitants

- Ipsilateral (to Lesion) Arm Exercise
- Contralateral (to Lesion) Head Movement
- Dizziness, Syncope, Ataxia
- Diplopia, Hemianopia, Blurred Vision
- Hearing Loss, Tinnitus

### Exam:

- R & L Brachial Artery  $\Delta \geq 15$  mmHg
- ↓ Amplitude Ipsilateral Radial Pulse
- Bruits: - Paraclavicular
- Carotid
- Suboccipital

### Dx:

- Duplex Ultrasound
  - Cerebrovascular
  - Upper Extremity
- +/- MRA, CTA

### Rx:

- Modifiable CV Risk Factors
- Endovascular Or Surgery

### Edu:

Majority w/ Subclavian Stenosis

↓  
No Steal

Majority w/ Steal → No Sx

Coronary-Subclavian Steal  
(CABG)