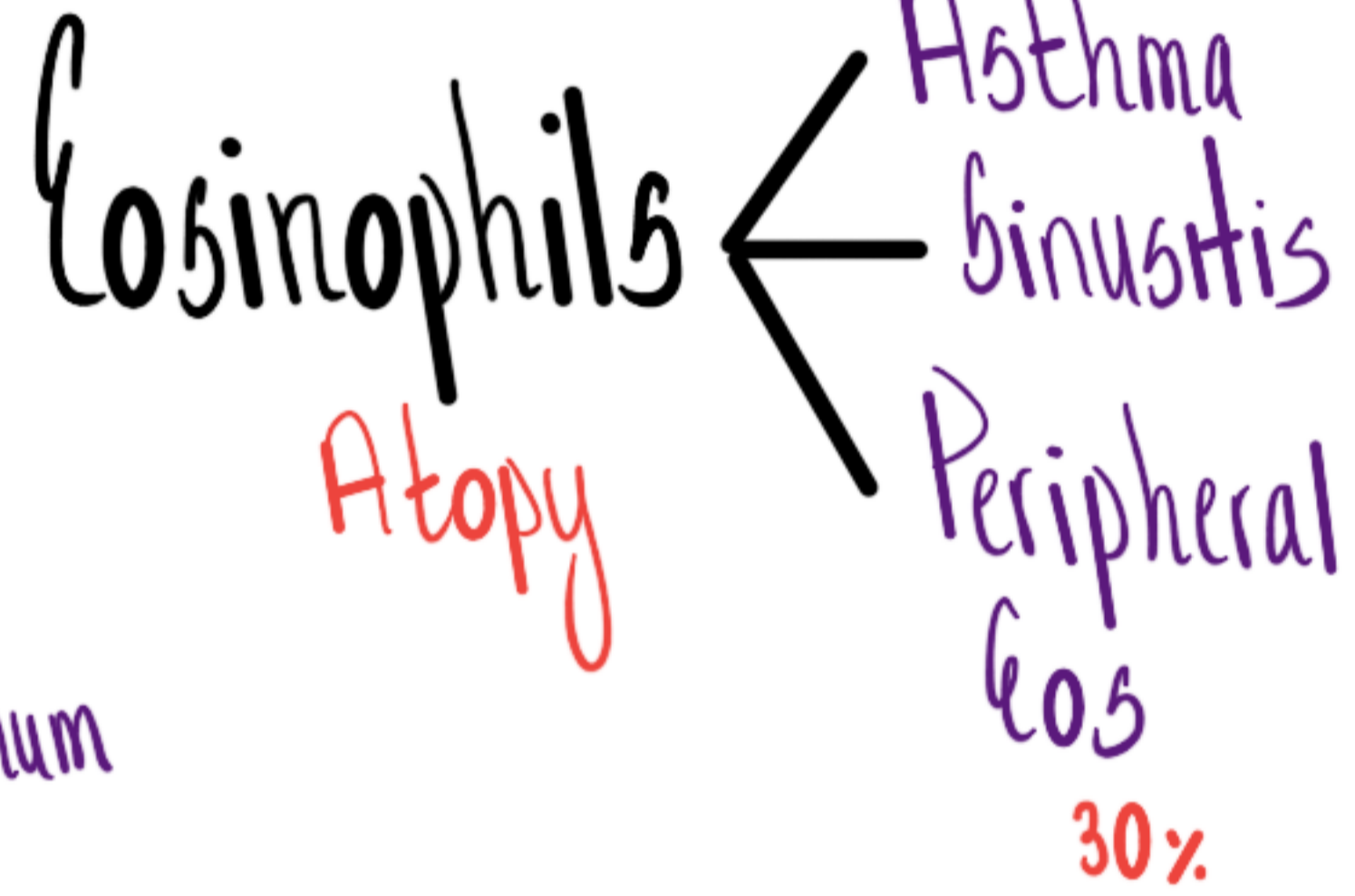
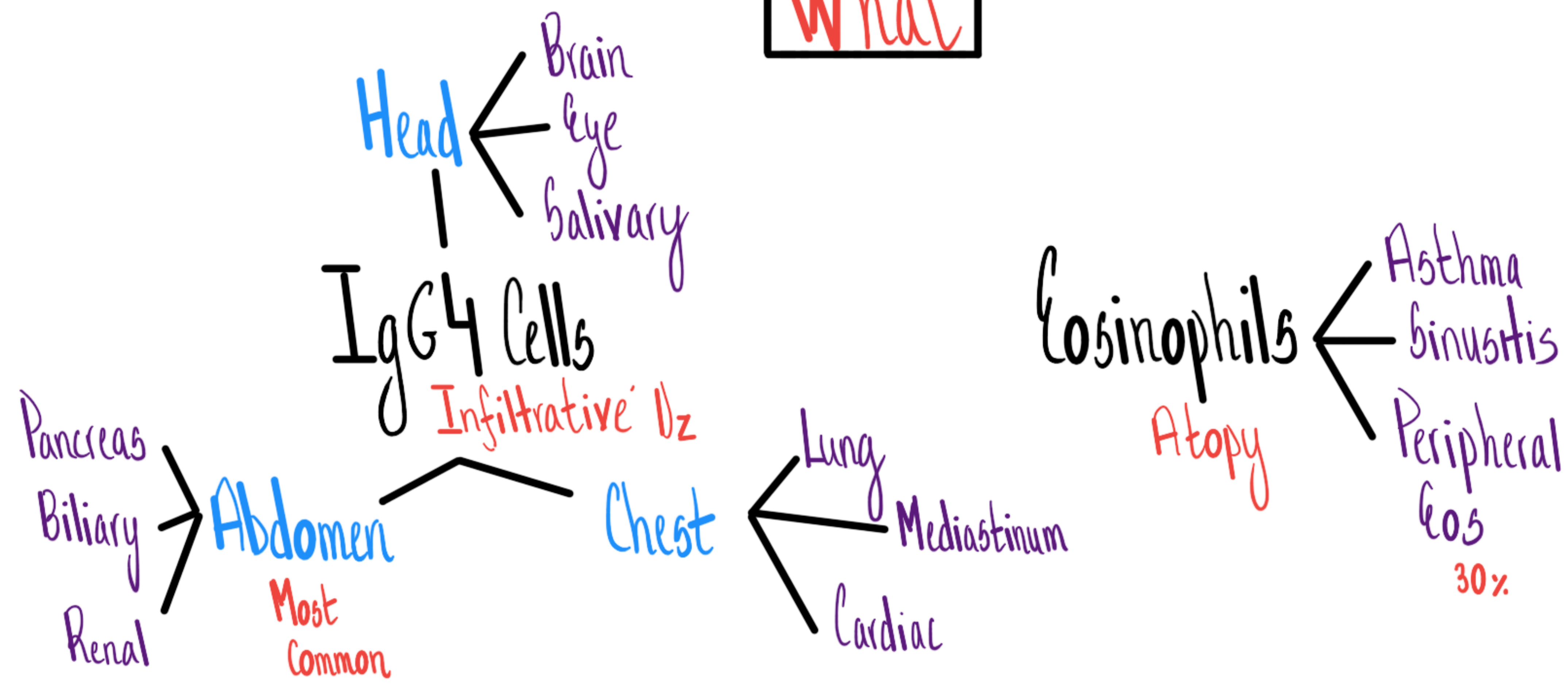


Who

M:F=3:1
Middle Age

IgG4 Dz

What



Phlebitis
Vasculitis
Large > Medium > Small
Aorta Iliac

Fibrosis
Chronic Dz

Dx

- Histology
- Clue
- ↑ serum IgG4 - Sen 80%
Spec 60%

DDx

- | | |
|-----------------|----------------------------------------|
| <u>Dx</u> | <u>Syndrome</u> |
| • Sjogren's | • Pancreatic/Salivary Mass/Enlargement |
| • sarcoidosis | • Retroperitoneal Dz |
| • Histiocytosis | • Vasculitis |

Rx

- Immunosuppression

Summary

Chronic Infiltrative Dz w/ Atopic + Vasculitic Features