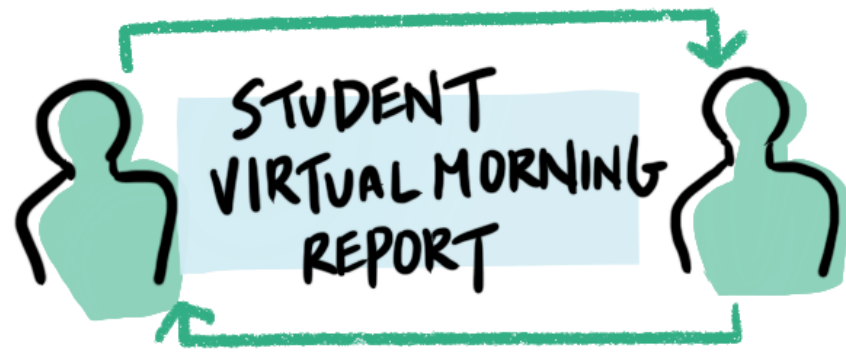

ANDREA
ALEX
DAN
DERECK ★
BRIANNA ★

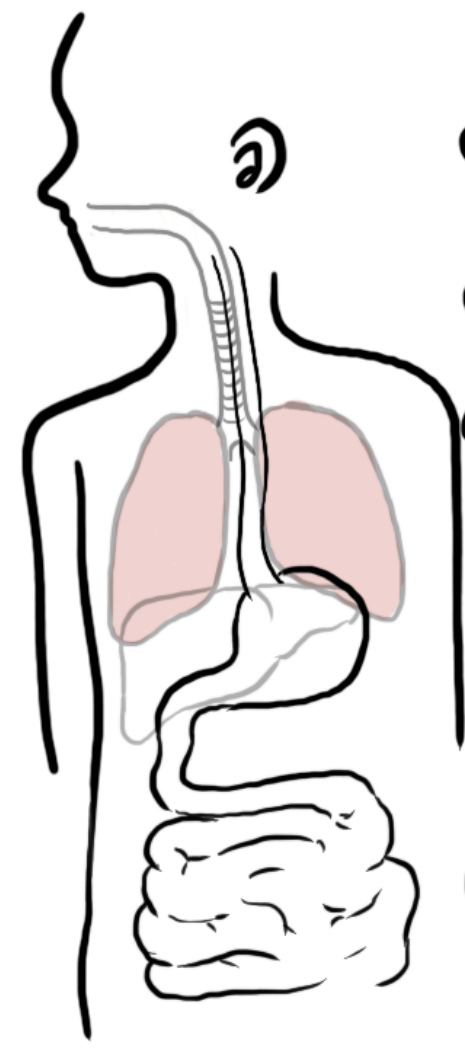
WHAT'S OUR CASE?
53 yo PERUVIAN MALE. HX OF ATOPY P/W ACUTE HEMOPTYSIS
W/ MULTISYSTEM SX. LABS/IMAGING c/w **EPGA**

HEMOPTYSIS

BUILD YOUR DIFFERENTIAL

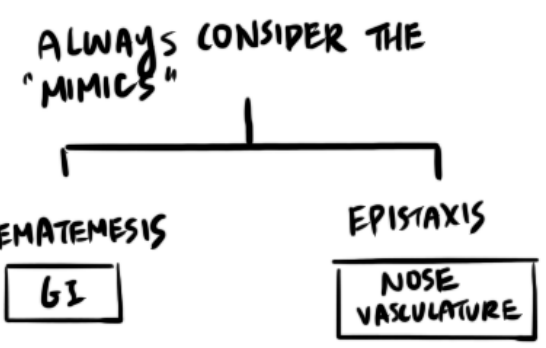
ANATOMICAL APPROACH

CONSIDER THE DDX



- ① **PULMONARY** (parenchyma)
- ② **VASCULAR**
- ③ **AIRWAY**

- MALIGNANCY**
- AUTOIMMUNE** [ANCA-mediated, cryo, LUPUS]
- PE**
- INFECTIOUS** [TB, ASPERGILLOSIS, CAVITARY PNA]
- OTHER** [BRONCHIECTASIS, CF]



MULTISYSTEM PICTURE

HEMOPTYSIS + LUNG + KIDNEY + SKIN + NEURO
PULMO-RENAL SYNDROME

CONSIDER THE LABS

- LEUKOCYTOSIS 17.7 ↑
- EOSINOPHILIA 600 ↑
- THROMBOCYTOSIS 649 ↑

can be NON-specific

+ (UA: **PROTEINURIA 4+ prot**
RBCs, RBC casts)

BUN: 35 CR: 2.29
suspect **SMALL VESSEL VASCULITIS**

CONSIDER IMAGING

DIFFUSE PULMO INFILTRATES
MEDIASTINAL LAD

KEY SCHEMA

PULMONARY - RENAL SYNDROMES

- ANCA VASCULITIS (pauci-immune) [GPA, MPA, EGPA]
- ANTI-GBM DISEASE (GOODPASTURES)
- LUPUS → ↓ complement
- CRYOGLOBULINEMIA → ↓ complement
- POST-INFECTIOUS GN

RENAL BIOPSY

EPGA

+ SKIN/LUNG BX