

CAVITARY LUNG LESIONS

Infection

Acute

NECROTIZING

- S. aureus
- S. pyogenes
- Klebsiella
- Pseudomonas

SEPTIC EMBOLI

- Tricuspid endocarditis
- Lemierre syndrome

Subacute

BACTERIA

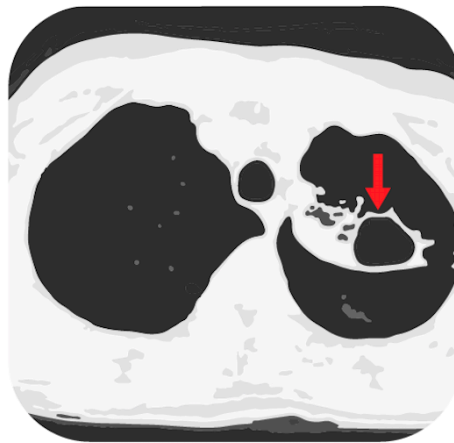
- Lung abscess
- S. milleri
- Mycobacteria
- Filamentous

FUNGI

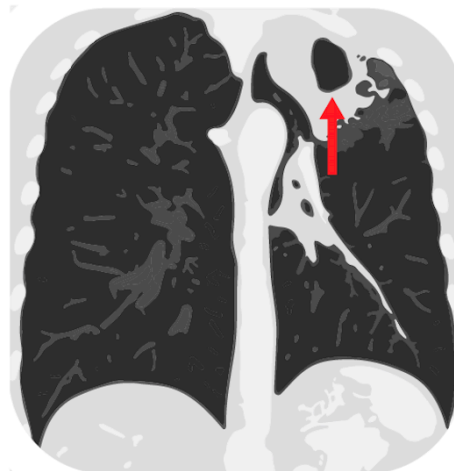
- Cryptococcus
- Endemic mycosis
- Molds

PARASITES

- Paragonimiasis
- Entamoeba



CT: Lucent area within the lung, surrounded by a wall of varied thickness.



Malignancy

Primary

- Squamous cell carcinoma (others less common)

Secondary

SOLID

- Squamous
- GI = GU

LIQUID

- Lymphoma
- Kaposi sarcoma
- Lymphomatoid granulomatosis

Autoimmune

- Granulomatosis with polyangiitis
- Rheumatoid arthritis
- Aseptic abscess syndrome

Other

- PE + infarct
- Foreign body granulomatosis

! Mimics !

- Bullae
- Cystic bronchiectasis

