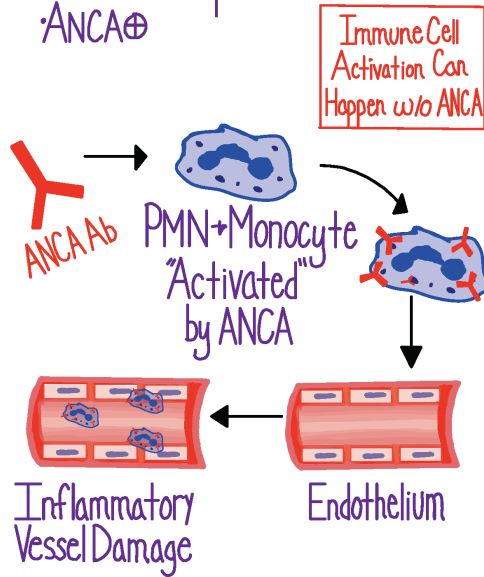


Granulomatosis with Polyangiitis

Overview

Small Vessel Vasculitis

- Normal complement
- ANCA ⊕



Epidemiology

- Rare
- Middle Age & Up
- M ≈ F
- More Common in Caucasians

Clinical Manifestations

Inflammation

- Fevers
- Malaise
- Arthralgias
- Weight Loss



Ear, Nose, Throat 85%

- Recurrent Sinusitis
- Recurrent Otitis
- Saddle-Nose Deformity

Lower Resp. Tract 60%

- Hemoptysis
- Subglottic Stenosis
- Pulmonary Nodules

Renal 75%

- AKI
- Glomerulonephritis

Skin 30%

- Leukocytoclastic Vasculitis
- Necrosis, Ulceration

Neurologic 30%

- Mononeuritis Multiplex
- Cranial Neuropathy

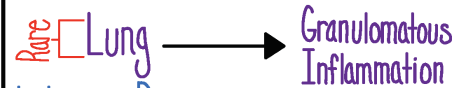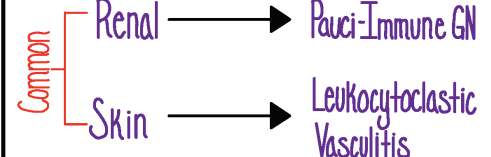
Ophtho 40%

- Scleritis/Episcleritis
- Corneal Ulcers

Diagnosis

With Biopsy

- Preferred
- ANCA ⊕ Biopsy



Without Biopsy

- NOT Preferred
- ANCA ⊕ Clinical Manifestations

Treatment

Glucocorticoids + Steroid-Sparing
ie. Methotrexate

⊕ ANCA in ~85% of cases
↳ c-ANCA/PR3 Most Common